


Complications and nightmare conditions

Case presentation from «Baku Health
Center

09.10.22

Dr. Zeynalov Rufat



Əsas ağırlaşmalar (texniki/yatrogen)

- Perforasiya
- Disseksiya
- No-reflow
- İtirilmiş alət və avadanlıq (stent, balon, tel və s.)
- Hemodinamik kollaps

Ağırlaşma düşünülür

Pasient 60 saniyə içində
reanimasiyon müdaxilə
olmadan yaşaya bilərmi?

HƏ

YOX

Düşün!

Əməliyyata keç

Köməyə çağır

Düşün!

Əməliyyata keç

Stabildi?

Y
O
X

Köməyə çağır

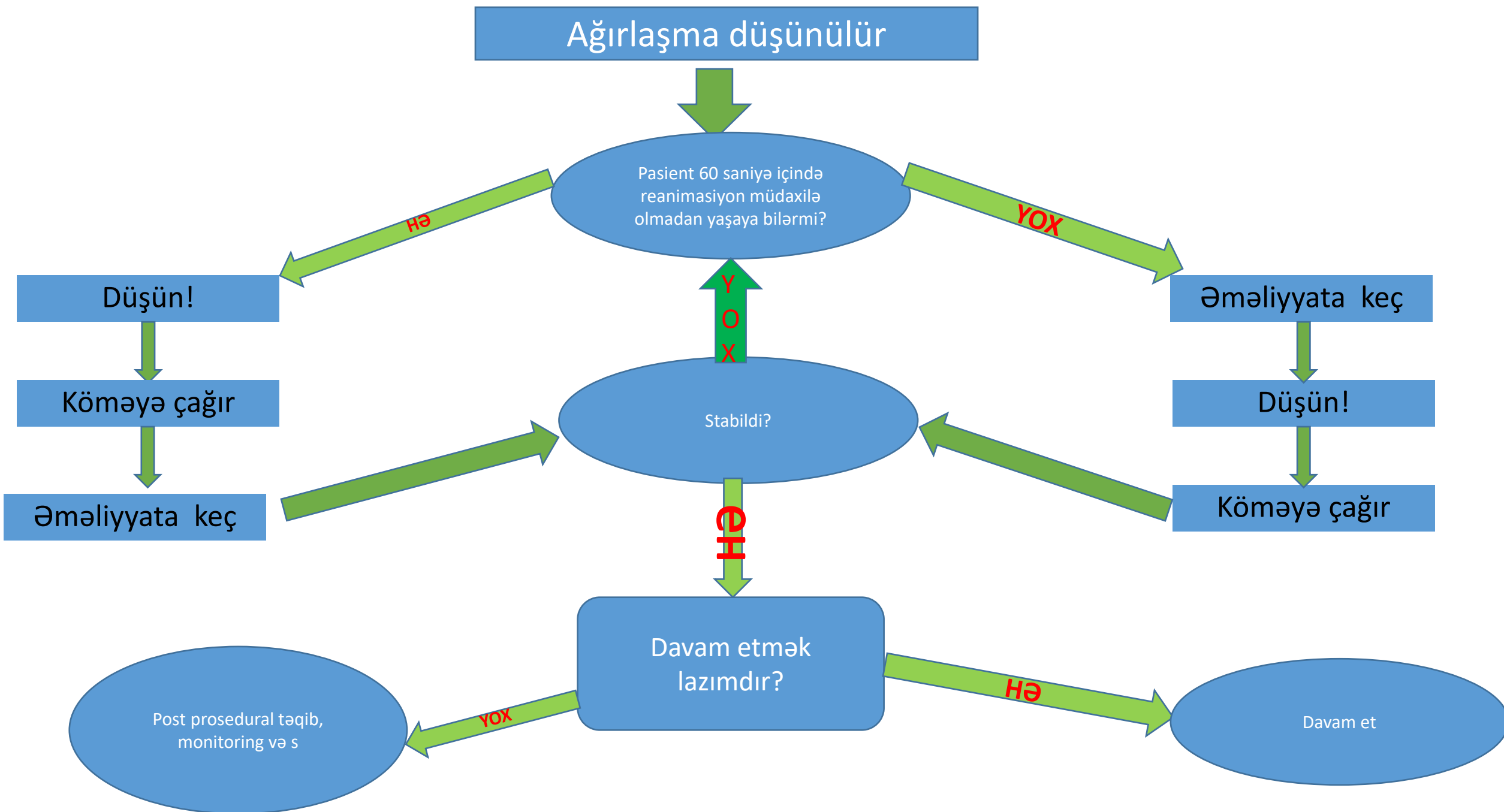
Davam etmək
lazımdır?

YOX

HƏ

Post prosedural təqib,
monitoring və s

Davam et





PTCA ağırlaşmalarına hazırsınız mı?



Arabada	Perikardiosentez seti
	Örtüklü stentlər
	Koil və onu çatdırın sistem
	Sneyer
	Trombin və mikrohissəciklər
Otaqda	MCSD (mexaniki dəstəkləyici)
	İlkin yardım arabası və defibrilyator
	Sizə yardım edə biləcək kolleqalarınız.
Xəstəxanada	ÜDC komandası
	Periferik invazivçi
	EXO cihazı
	Təcrübəli İCU

Case -1

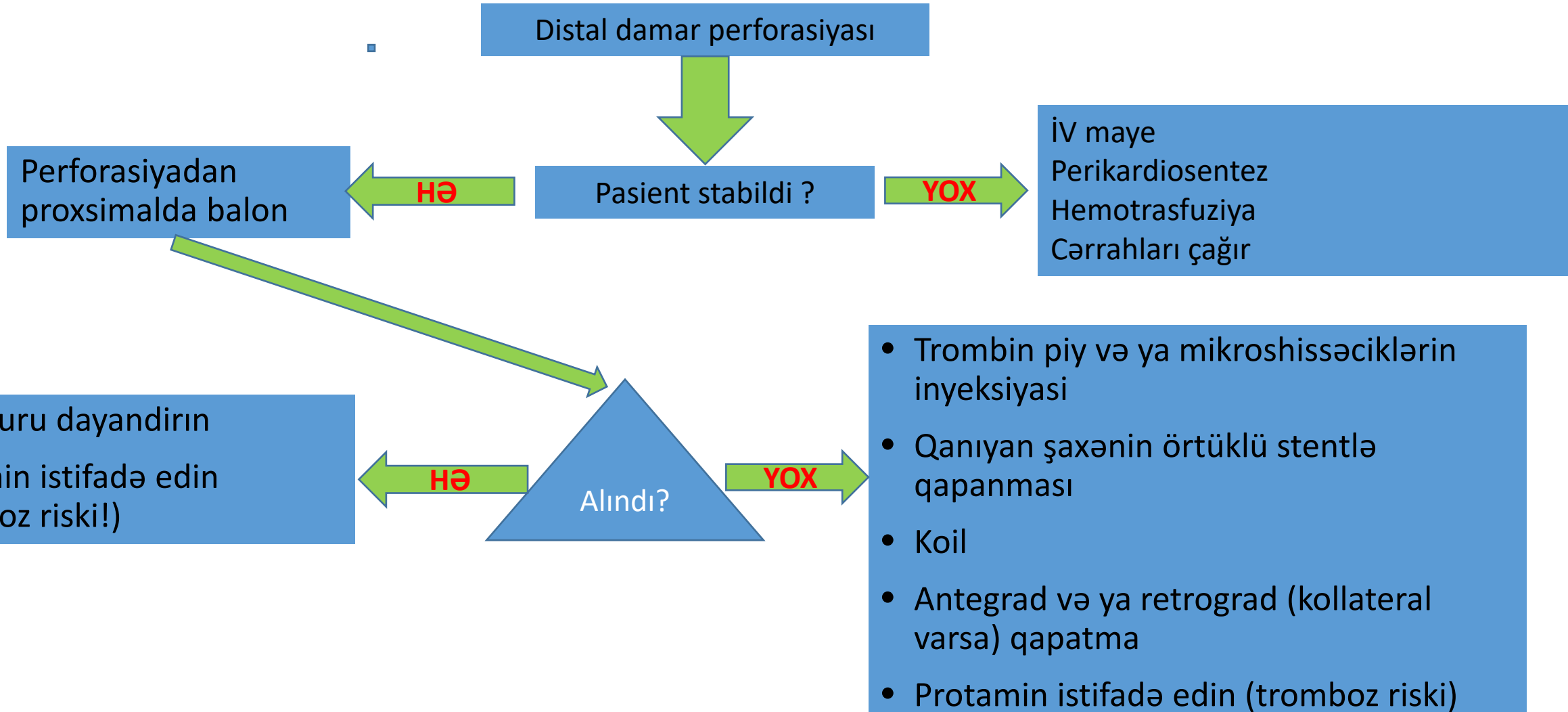
- Q, 51 y.
- Qeyri –stabil stenokardiya.
- AH



CTO –lad açıldı , Lad prox -2,75 x 14, mid 2,25 x 22 DES.







Distal damar perforasiyası








Thermo hydropearl maddəsi ilə okkluziya







Case-2



- K, 51y
- Lateral STEMI

		
---	---	---

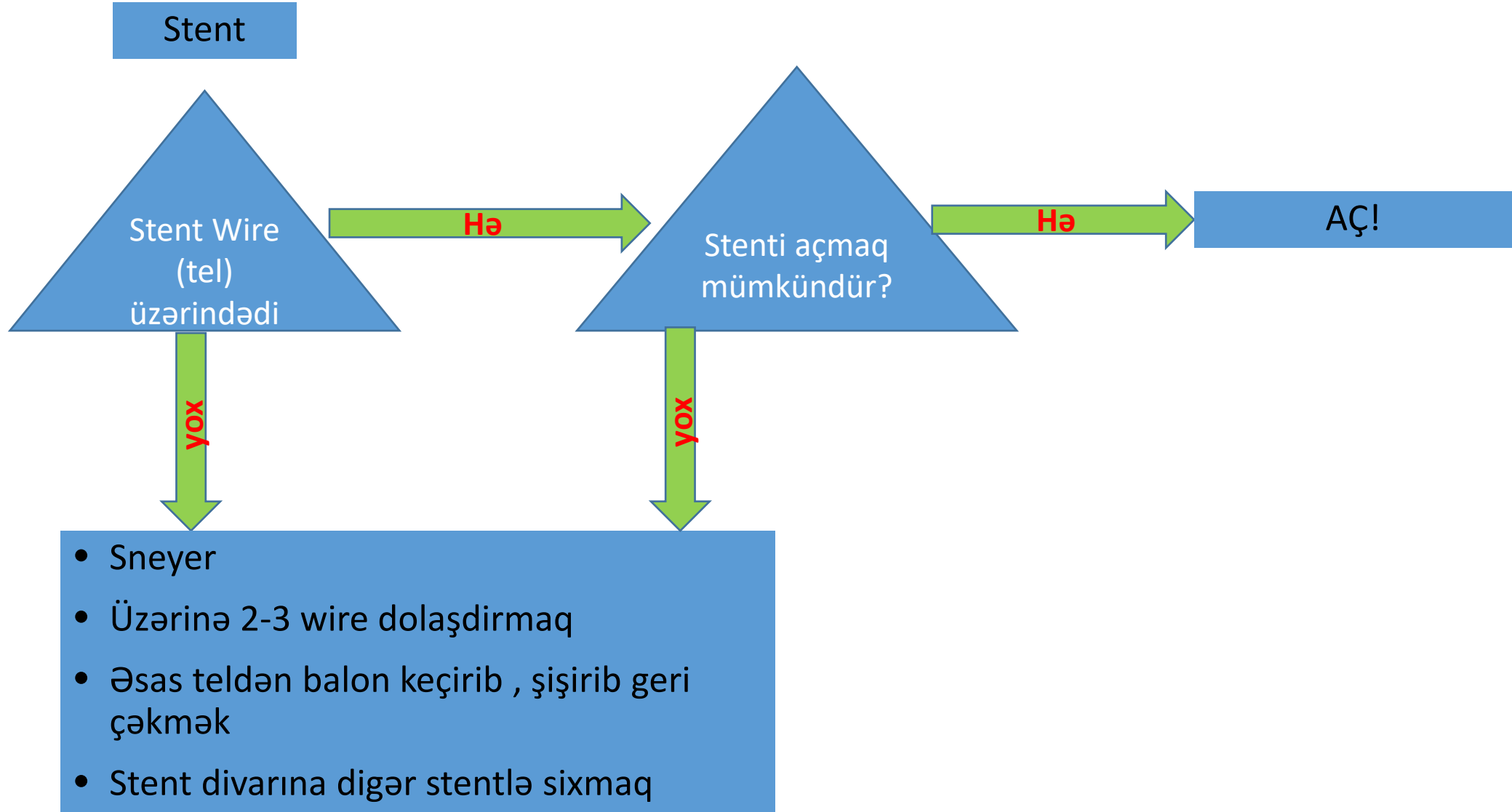
Cx –prox 3 x18 DES











İtirilmiş avadanlıq -stent










Cx-dist 2,25 x 28 DES









Nəticə

- Xəstə stabil vəziyyətdə evə yazılır


Case -3

- 72 y, qadın
- AH
- Qeyri stabil stenokardiya


RCA- dist 2,25 x 22





RCA mid 2,5 x 30 DES







RCA prox 2,75 x 30 DES



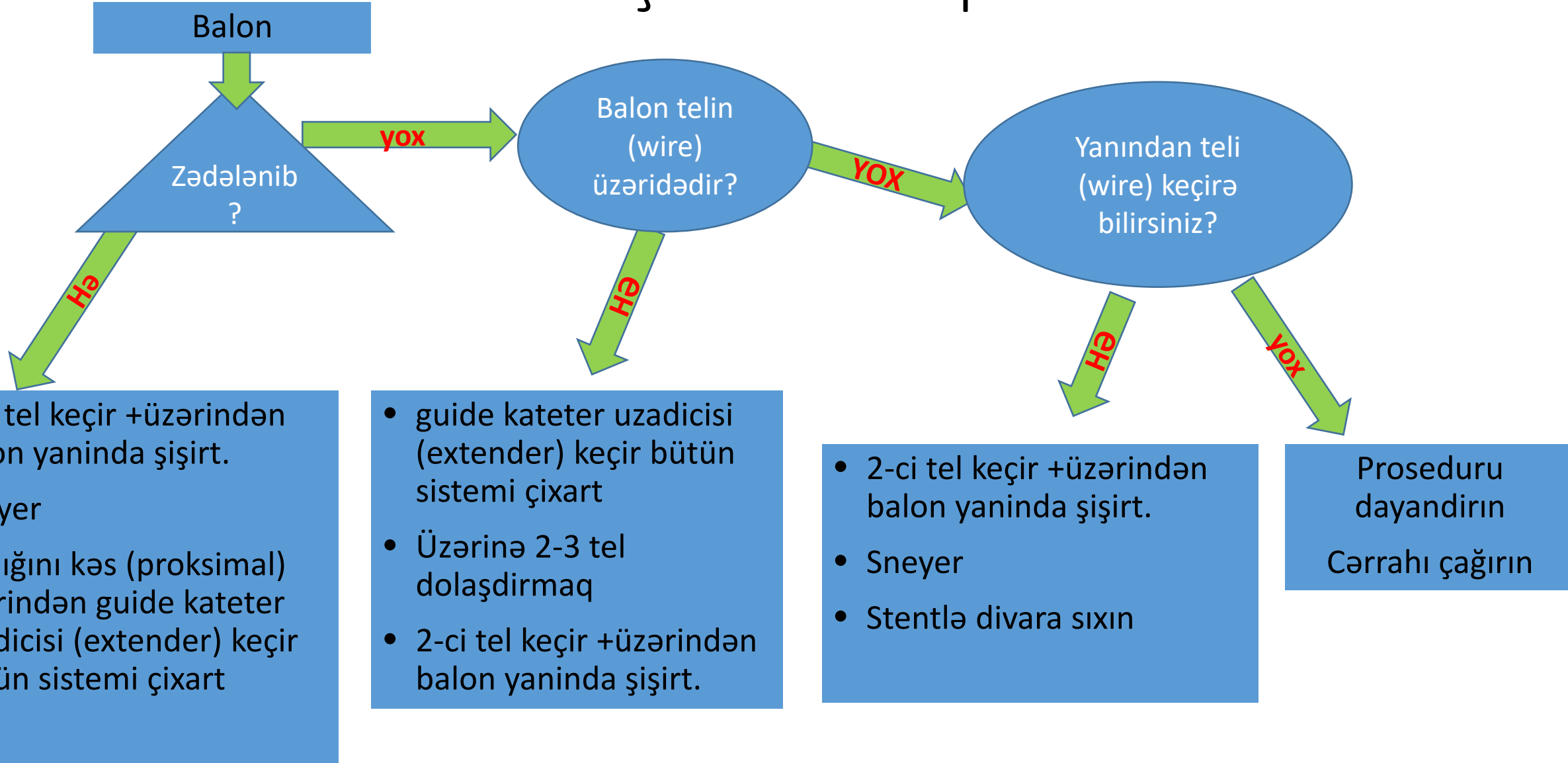




Proseduru «ideal» bitirmək üçün RCA –distal stent 2,5 x 6 NC
postdilatasiya











İtirilmiş avadanlıq -balon







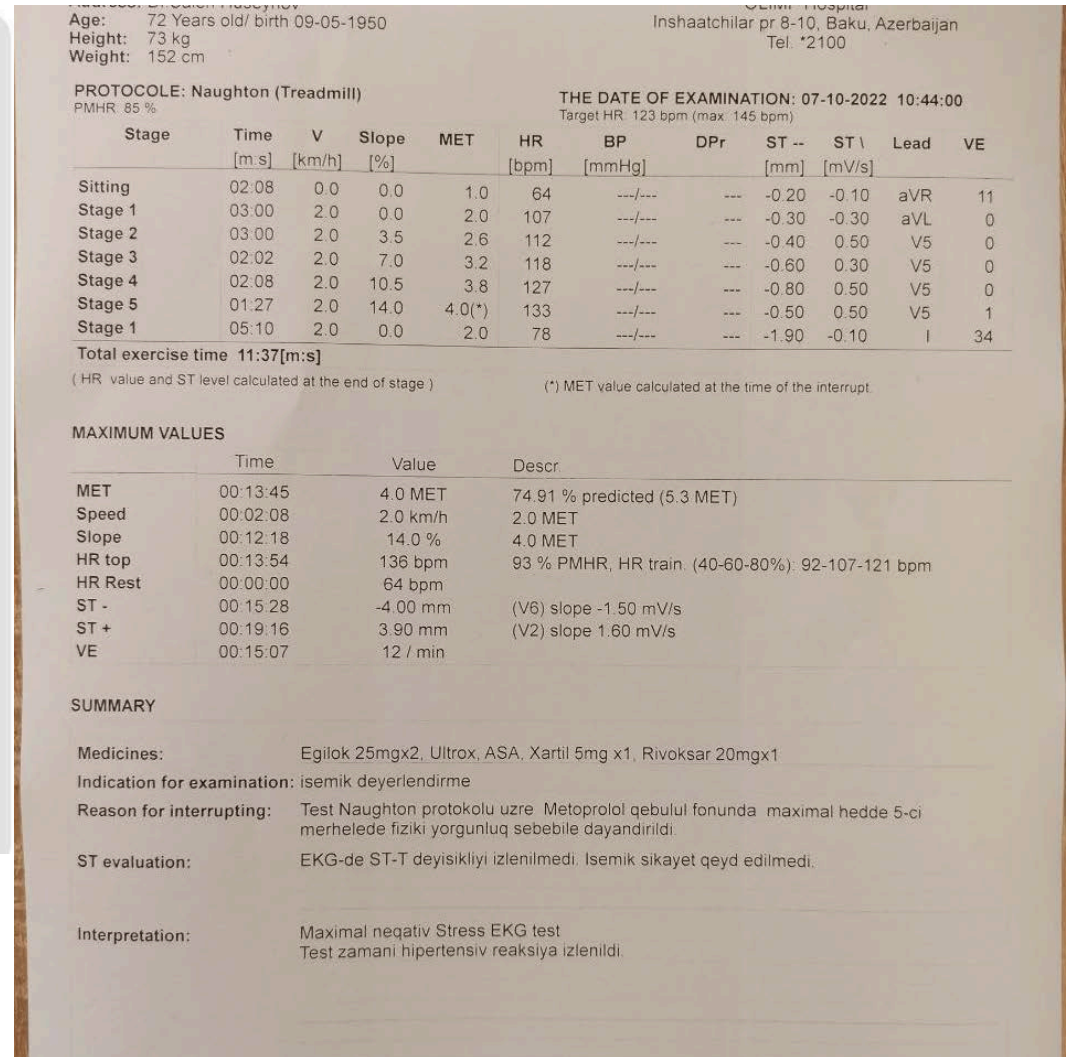
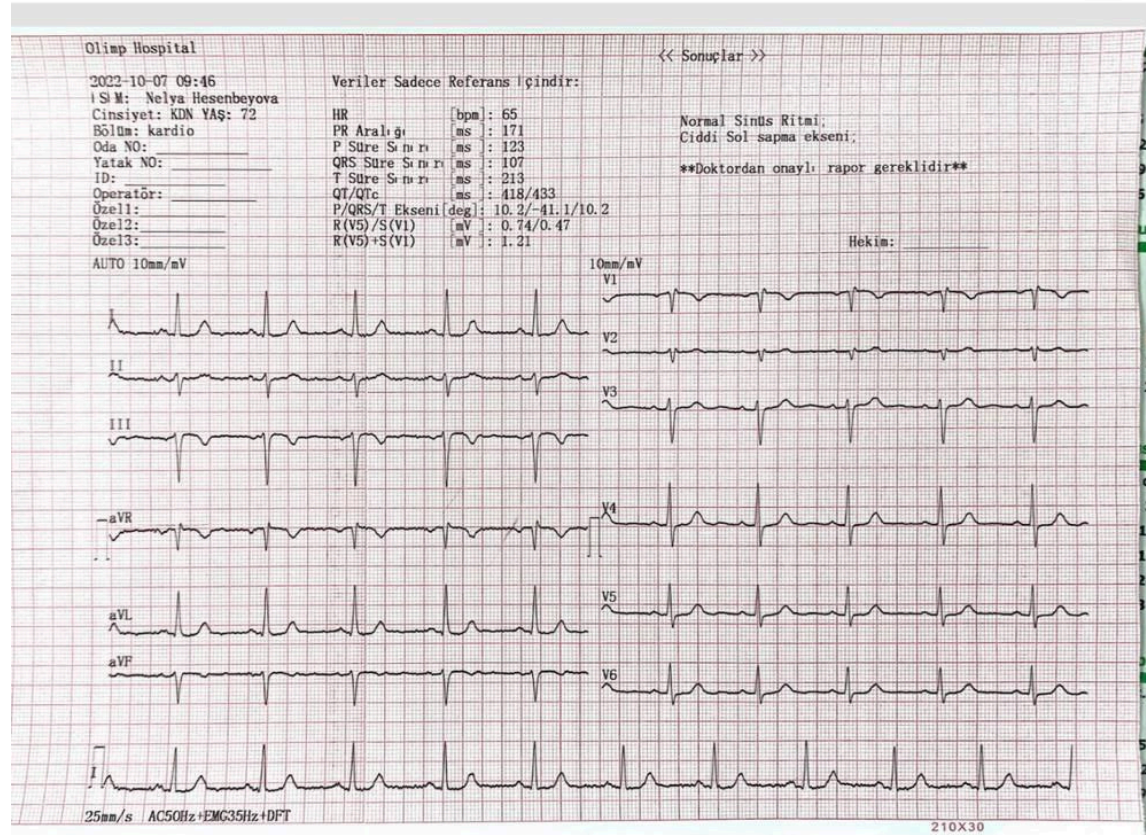




Nəticə:

- Prosedur dayandırıldı
- Xəstə intensiv terapiya şöbəsinə köçürülür.
- 3 gün sonra evə yazılır.

15 ay sonra kontrol (07.10.22)



15 ay sonra kontrol (07.10.22)



Özümüzə qarşı tələbkar olsaq, nəinki uğurumuz, səhvlərimiz də bilik mənbəyi olacaq.

Hipokrat.